

# Hysterosalpingography: A Reemerging Study<sup>1</sup>

William L. Simpson, Jr, MD • Laura G. Beitia, MD • Jolinda Mester, MD

## TEACHING POINTS

See last page

Hysterosalpingography (HSG) has become a commonly performed examination due to recent advances and improvements in, as well as the increasing popularity of, reproductive medicine. HSG plays an important role in the evaluation of abnormalities related to the uterus and fallopian tubes. Uterine abnormalities that can be detected at HSG include congenital anomalies, polyps, leiomyomas, surgical changes, synechiae, and adenomyosis. Tubal abnormalities that can be detected include tubal occlusion, salpingitis isthmica nodosum, polyps, hydrosalpinx, and peritubal adhesions. Some complications can occur with HSG—most notably, bleeding and infection—and awareness of the possible complications of HSG is essential. Nevertheless, HSG remains a valuable tool in the evaluation of the uterus and fallopian tubes. Radiologists should become familiar with HSG technique and the interpretation of HSG images.

©RSNA, 2006

**Abbreviations:** ESR = erythrocyte sedimentation rate, HSG = hysterosalpingography, PID = pelvic inflammatory disease, SIN = salpingitis isthmica nodosum

**RadioGraphics 2006;** 26:419–431 • **Published online** 10.1148/rg.262055109 • **Content Codes:** **GU** **OB**

<sup>1</sup>From the Department of Radiology, Mount Sinai Medical Center, Box 1234, 1 Gustave L. Levy Place, New York, NY 10029. Presented as an education exhibit at the 2004 RSNA Annual Meeting. Received May 4, 2005; revision requested June 3 and received July 28; accepted July 29. All authors have no financial relationships to disclose. **Address correspondence to** W.L.S. (e-mail: [william.simpson@mountsinai.org](mailto:william.simpson@mountsinai.org)).

©RSNA, 2006

## Introduction

Hysterosalpingography (HSG) is the radiographic evaluation of the uterus and fallopian tubes and is used predominantly in the evaluation of infertility. Other indications for HSG include the evaluation of women with a history of recurrent spontaneous abortions, the postoperative evaluation of women who have undergone tubal ligation or reversal of tubal ligation, and the assessment of patients prior to myomectomy (Table). The primary role of HSG is in the evaluation of the fallopian tubes. Ultrasonography (US) is currently used for evaluation of the endometrium (ie, abnormal uterine bleeding, polyps) and pregnancy, whereas magnetic resonance (MR) imaging is used more in the evaluation of the uterine myometrium (ie, uterine contour, myomas) and the ovaries. In our practice, however, the number of HSG examinations has increased dramatically over the past few years. This increase is likely due to (a) advances in reproductive medicine, resulting in more successful in vitro fertilization procedures (1); and (b) the trend toward women delaying pregnancy until later in life (2). With the increased demand for HSG, radiologists should be familiar with HSG technique and the interpretation of HSG images. In this article, we review the imaging technique and possible complications of HSG. We also discuss and illustrate a variety of abnormalities of the uterus and fallopian tubes that can be assessed with HSG.

## HSG Technique

In this section, we discuss the HSG technique that works best in our practice. Other HSG techniques that provide equally valuable diagnostic information have been described previously (3).

No specific patient preparation is required for HSG. Because patients may experience cramping during the examination, women are advised to take a nonsteroidal anti-inflammatory drug 1 hour prior to the procedure. **There are two contraindications for HSG: pregnancy and active pelvic infection. The examination should be scheduled during days 7–12 of the menstrual cycle (day 1 being the first day of menstrual bleeding). The endometrium is thin during this proliferative phase, a fact that facilitates image interpretation and should also ensure that there is no pregnancy.** The patient should be instructed to abstain from sexual intercourse from the time menstrual bleeding ends until the day of the study to avoid a potential pregnancy. If the patient has irregular menstrual cycles or there is a possibility of pregnancy, the serum  $\beta$ -human chorionic gonadotropin level is evaluated. We use the erythrocyte sedimentation rate (ESR) to check for active

## Indications for HSG

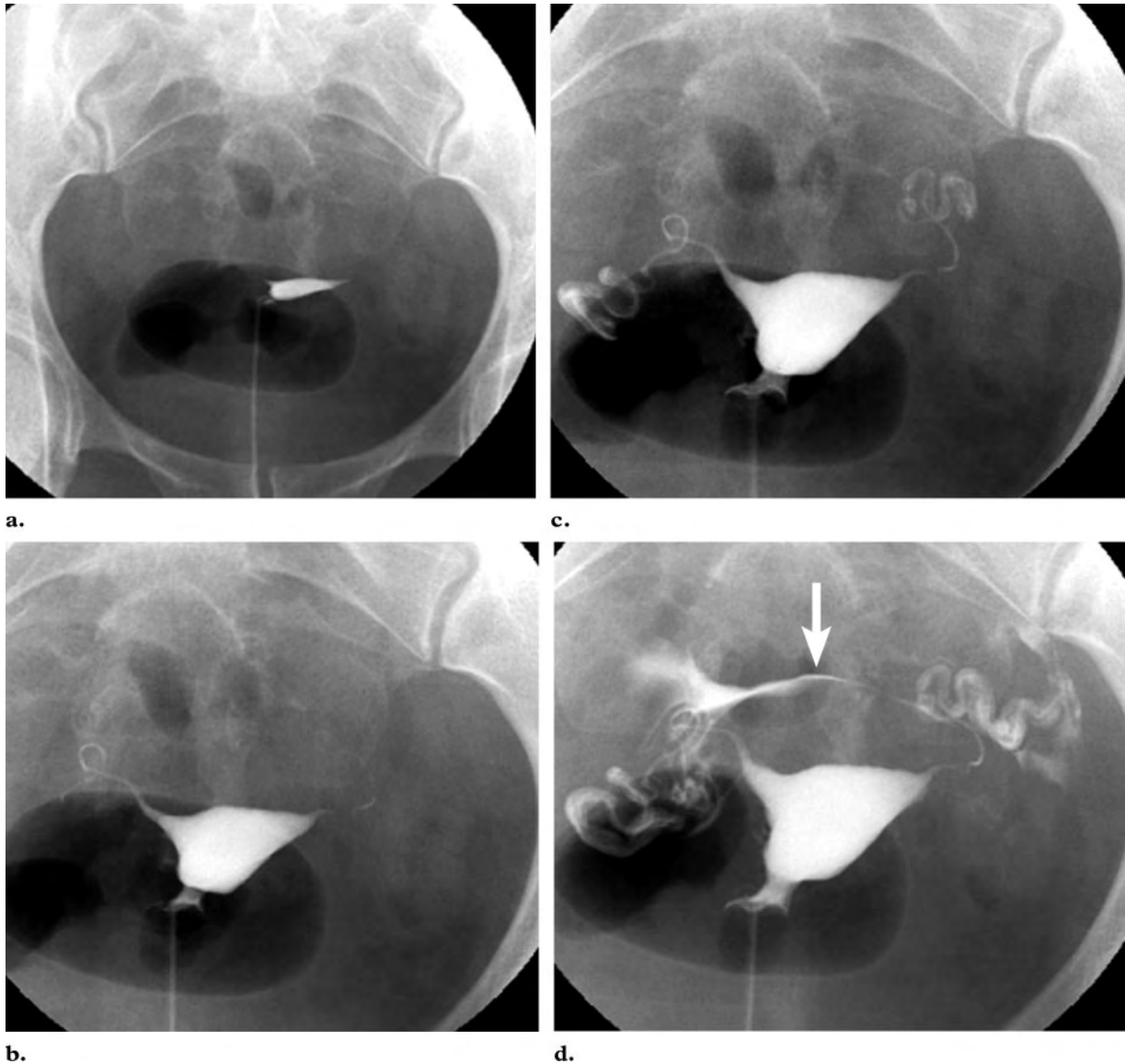
Infertility Recurrent spontaneous abortions Postoperative evaluation following tubal ligation or reversal of tubal ligation Preoperative evaluation prior to myomectomy
--

pelvic infection, which will cause the ESR to be elevated. In patients with a coexistent inflammatory condition (ie, arthritis, sarcoidosis, collagen vascular disease) that may result in an elevated ESR, negative gonorrhea and chlamydia cultures are acceptable. Decisions concerning prophylactic use of antibiotics in patients with a history of pelvic inflammatory disease (PID) are left to the referring clinicians. We do not routinely require prophylactic antibiotic treatment in patients with a history of PID.

The patient is placed supine on the fluoroscopy table in the lithotomy or modified lithotomy position. The perineum is prepared with povidone-iodine solution (Betadine; Purdue, Stamford, Conn) and draped with sterile towels. A speculum is inserted into the vagina. The cervix is localized and cleansed with povidone-iodine solution. A 5-F HSG catheter (Cooper Surgical, Trumbull, Conn) is positioned in the cervical canal. The balloon is inflated fully (or to the extent that the patient can tolerate, since this maneuver may cause cramping). We place a metallic marker over one side of the pelvis to indicate the right or left side of the patient. A scout radiograph of the pelvis is obtained with the catheter in place before contrast material is instilled. Water-soluble contrast material (Isovue-300; Bracco, Princeton, NJ) is then slowly instilled, with fluoroscopic images obtained intermittently to evaluate the uterus and fallopian tubes. We obtain four spot radiographs (Fig 1) after the scout radiograph. The first image (Fig 1a) is obtained during early filling of the uterus and is used to evaluate for any filling defect or contour abnormality. Small filling defects are best seen at this stage. The second image (Fig 1b) is obtained with the uterus fully distended. The shape of the uterus is best evaluated at this stage, although small filling defects may be obscured when the uterus is well opacified. The third image (Fig 1c) is obtained to demonstrate and evaluate the fallopian tubes. The fourth image (Fig 1d) should exhibit free intraperitoneal spillage of contrast material. Additional spot radiographs are obtained to document any abnormality that is seen. Oblique views of the fallopian tubes may be obtained as needed to “elongate” the tubes or displace superimposed structures. A radiograph is usually obtained at the end of the study with the balloon deflated to evaluate the

### Teaching Point

### Teaching Point



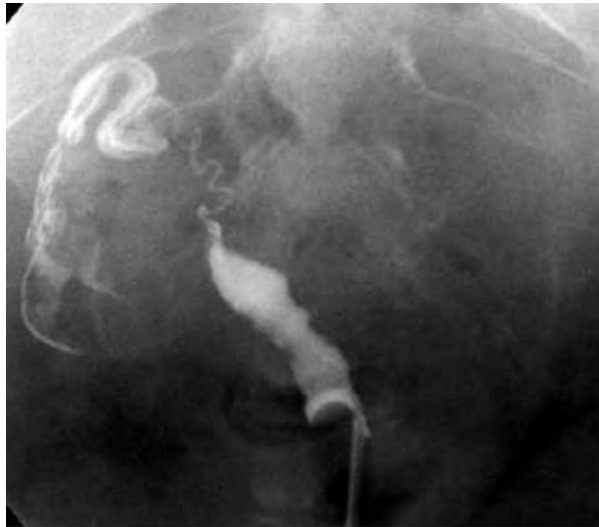
**Figure 1.** (a) Spot radiograph obtained during the early filling stage of the uterus. Small filling defects are best seen at this stage. (b) On a radiograph obtained with the uterus fully distended with contrast material, portions of both fallopian tubes are opacified. Like images obtained during the early filling stage of the uterus, images obtained at full uterine distention allow evaluation for filling defects and contour abnormalities. However, small filling defects may be obscured when the uterus is well opacified. (c) Spot radiograph clearly depicts the interstitial, isthmic, and ampullary portions of both fallopian tubes. (d) Spot radiograph shows intraperitoneal contrast material spillage from the fallopian tubes. In this case, the spillage outlines the convexity of the uterine fundus (arrow).

lower uterine segment if the balloon obscured this area after initial placement or migrated into this area during the study. We do not use a tenaculum; if traction on the uterus is needed, it can usually be provided by gently pulling down on the HSG catheter.

### Complications of HSG

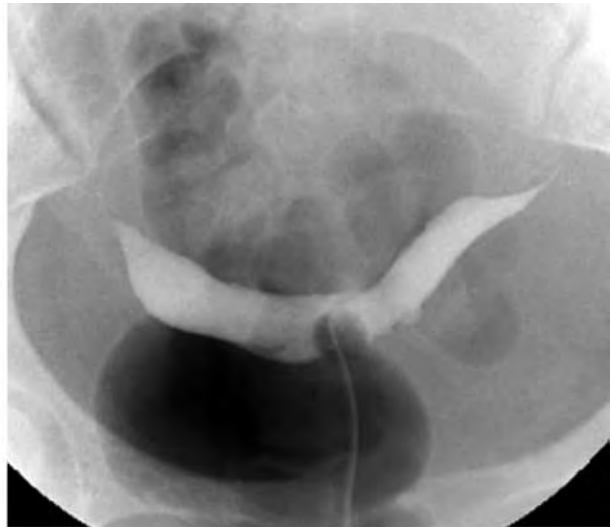Some complications can occur with HSG, the two most common of which are bleeding and infection. The patient should be made aware that she may experience light spotting after the procedure, usually lasting less than 24 hours, especially if the catheter balloon irritates the endocervical

canal or is pulled to provide uterine traction. The exclusive use of sterile instruments minimizes the risk of infection. Patients are instructed to watch for the development of fever or foul-smelling vaginal discharge over the 2–4-day period following the procedure. Patients usually experience some cramping when the catheter balloon is inflated in the endocervical canal or when the uterus is well distended with contrast material. Cramping is more common in the setting of a tubal obstruction. This cramping is generally minor and transient and is well tolerated by the majority of patients. However, some patients may experience

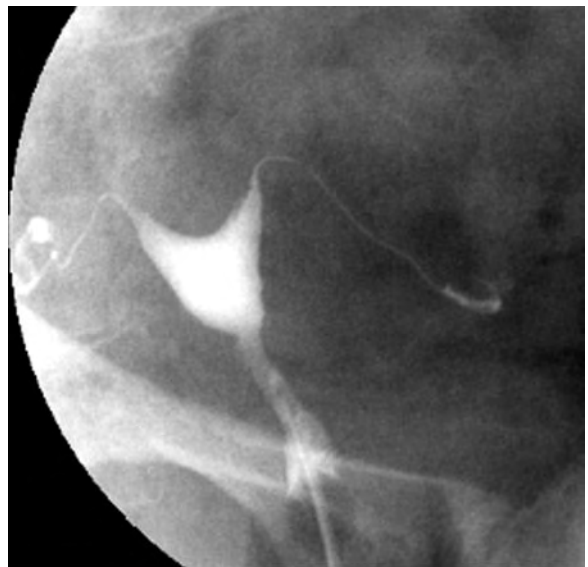

2.

**Figures 2–4.** (2) Unicornuate uterus. Spot radiograph demonstrates a single uterine horn with an irregular medial contour. A single fallopian tube is also visualized. (3) Bicornuate uterus. Spot radiograph shows two markedly splayed uterine horns. The fallopian tubes are not visualized at this imaging stage. (4) Septate and arcuate uterus. Spot radiograph demonstrates a depression of the uterine fundus, a finding that may represent a short septum or an arcuate deformity.



3.



4.

severe pain, leading to premature termination of the procedure or, rarely, a vasovagal reaction.

Other potential complications are extremely rare. There is the potential for a reaction to the contrast material (3); however, such a reaction is very uncommon with the use of currently available low-osmolar nonionic contrast agents. There is also the potential for a systemic reaction to the contrast material if vascular intravasation occurs. In general, however, lymphatic or vascular intravasation is clinically insignificant and not dangerous. Perforation of the uterus or fallopian tubes is another extremely infrequent complication. Finally, there is the potential for irradiation of an early, unsuspected pregnancy. Appropriate timing of the examination and a negative pregnancy test in dubious circumstances should minimize this potential risk.

### Uterus

The uterus is a muscular sac that houses the fetus during gestation. The size of the uterus varies depending on the patient's age and parity. HSG is helpful in the evaluation of the uterine cavity only, providing indirect information about the remainder of the uterus. The uterine cavity is triangular, with the base directed cranially and the apex caudally. The cervix constitutes the most inferior aspect of the uterus and extends into the vagina. The isthmus is the uterine portion imme-

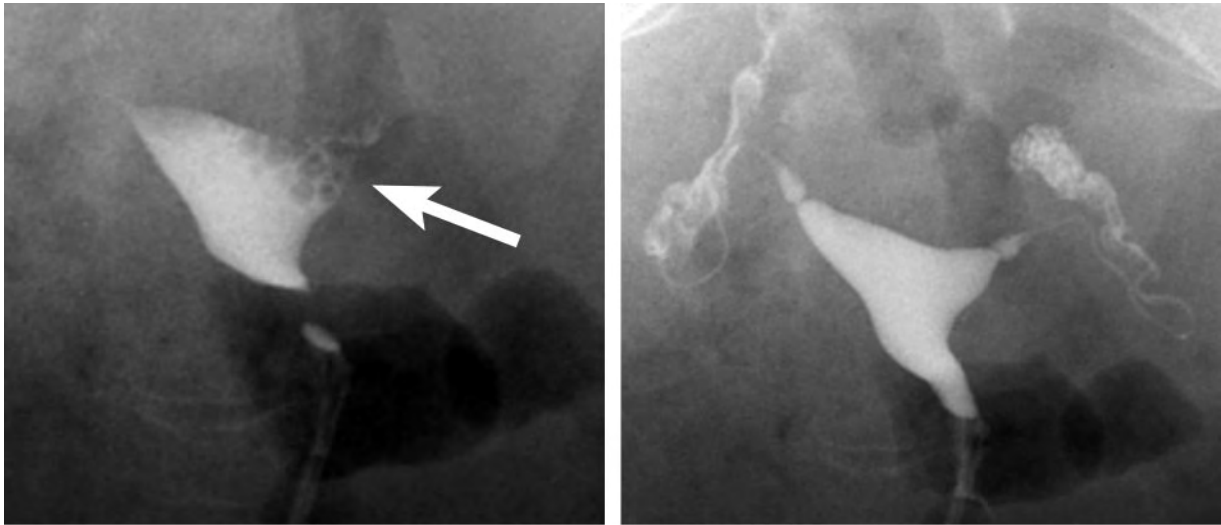
diately above the cervix. The majority of the uterus is composed of the body, or corpus. The uppermost aspect of the uterus is the fundus, which can be concave, flattened, or slightly convex. The fallopian tubes connect to the fundus at the cornua, or lateral extremes of the base of the triangular cavity.

At HSG, the uterus should look like an inverted triangle with well-defined, smooth contours (Fig 1b). **Uterine anomalies can be due to (a) congenital abnormalities of uterine shape, (b) luminal filling defects, or (c) abnormalities of uterine contour.**

**Teaching Point**

### Congenital Abnormalities of Uterine Shape

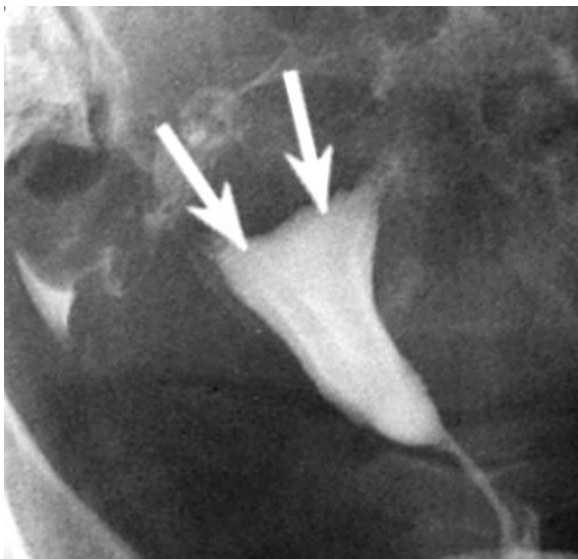
Congenital abnormalities of uterine shape are due to abnormal fusion of the müllerian ducts during early (6–12 weeks) gestation (4). A unicornuate uterus (Fig 2) results if one of the müllerian ducts



a.

b.

**Figure 5.** Air bubbles. (a) Spot radiograph shows air bubbles (arrow) in the left side of the uterus. (b) Spot radiograph no longer depicts the air bubbles seen in the left cornua of the uterus in a. Air bubbles are often mobile or transient when they are expelled into the fallopian tubes.



**Figure 6.** Uterine folds. HSG spot radiograph demonstrates uterine folds (arrows) as linear filling defects that parallel the longitudinal axis of the uterus. Uterine folds are normal findings that are occasionally seen at HSG.

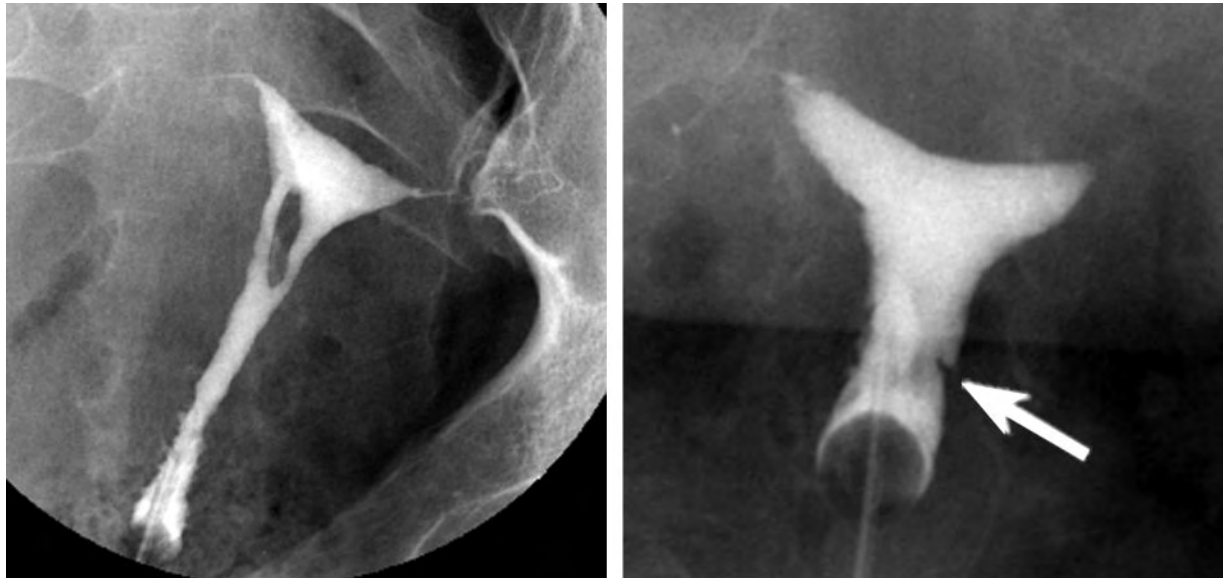
does not form properly. If the two müllerian ducts do not completely fuse, a bicornuate uterus is formed (Fig 3). All bicornuate uteri will demonstrate a cleft in the outer contour of the fundus. The amount of fusion of the müllerian ducts can vary from minimal union to nearly complete union. When the two ducts fuse but there is incomplete resorption of the intervening septum, a septate uterus results (Fig 4). The length of the septum can vary depending on the degree of resorption (complete vs partial septum), similar to the bicornuate uterine anomaly. An arcuate uterus is considered by some to be a mild form of

septate uterus in which there is mild concavity of the uterine cavity in the fundus. Unlike the bicornuate uterine deformity, the septate and arcuate deformities have a normal outer uterine contour. Optimal visualization of the outer contour is important in differentiating among these various anomalies. Thus, MR imaging has become the preferred imaging modality rather than HSG. In recent years, the introduction of three-dimensional US has allowed visualization of the outer uterine contour with this modality as well. Three-dimensional transvaginal US promises to play an important role in contour evaluation. Because the genital and urinary systems develop embryologically from a common ridge of mesoderm, congenital abnormalities of the uterus are often accompanied by renal abnormalities.

### Luminal Filling Defects

Filling defects are common findings at HSG. Care should be taken to flush the catheter thoroughly with contrast material to avoid injecting air bubbles. Air bubbles manifest as well-circumscribed lucencies that collect in the nondependent portion of the uterus. They are often mobile or transient when they are expelled into the fallopian tubes. This fact can help differentiate air bubbles from fixed filling defects (Fig 5). Despite the best efforts, air bubbles are occasionally seen.

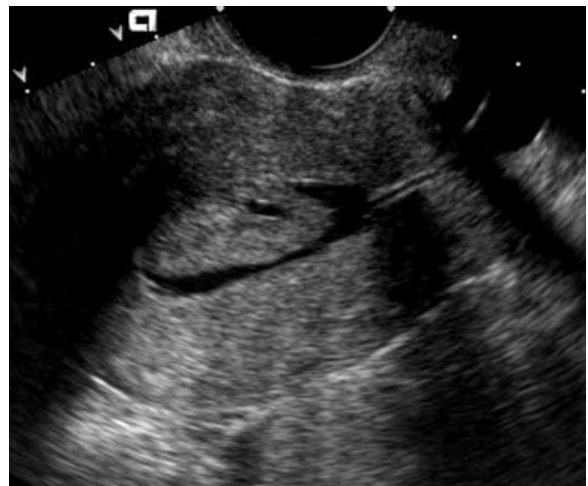Uterine folds are normal variants that are occasionally seen at HSG. They are believed to be caused by infolding of the inner aspect of the myometrium in an underdistended uterus. Uterine folds parallel the long axis of the uterus and can extend into the uterine horns (Fig 6) (5).



**Figure 7.** Synechiae. **(a)** Spot radiograph shows a central oval filling defect within the uterus, a finding that represents a synechia. **(b)** Spot radiograph obtained in a different patient demonstrates a short linear defect (arrow) along the inferior left side near the uterine isthmus.

Synechiae are intrauterine adhesions that result from scarring, most commonly secondary to the endometrial trauma of curettage. Endometrial infections may also result in synechia formation. Synechiae manifest as irregular filling defects, most commonly as linear filling defects arising from one of the uterine walls (Fig 7). Multiple synechiae associated with infertility is known as Asherman syndrome (6).

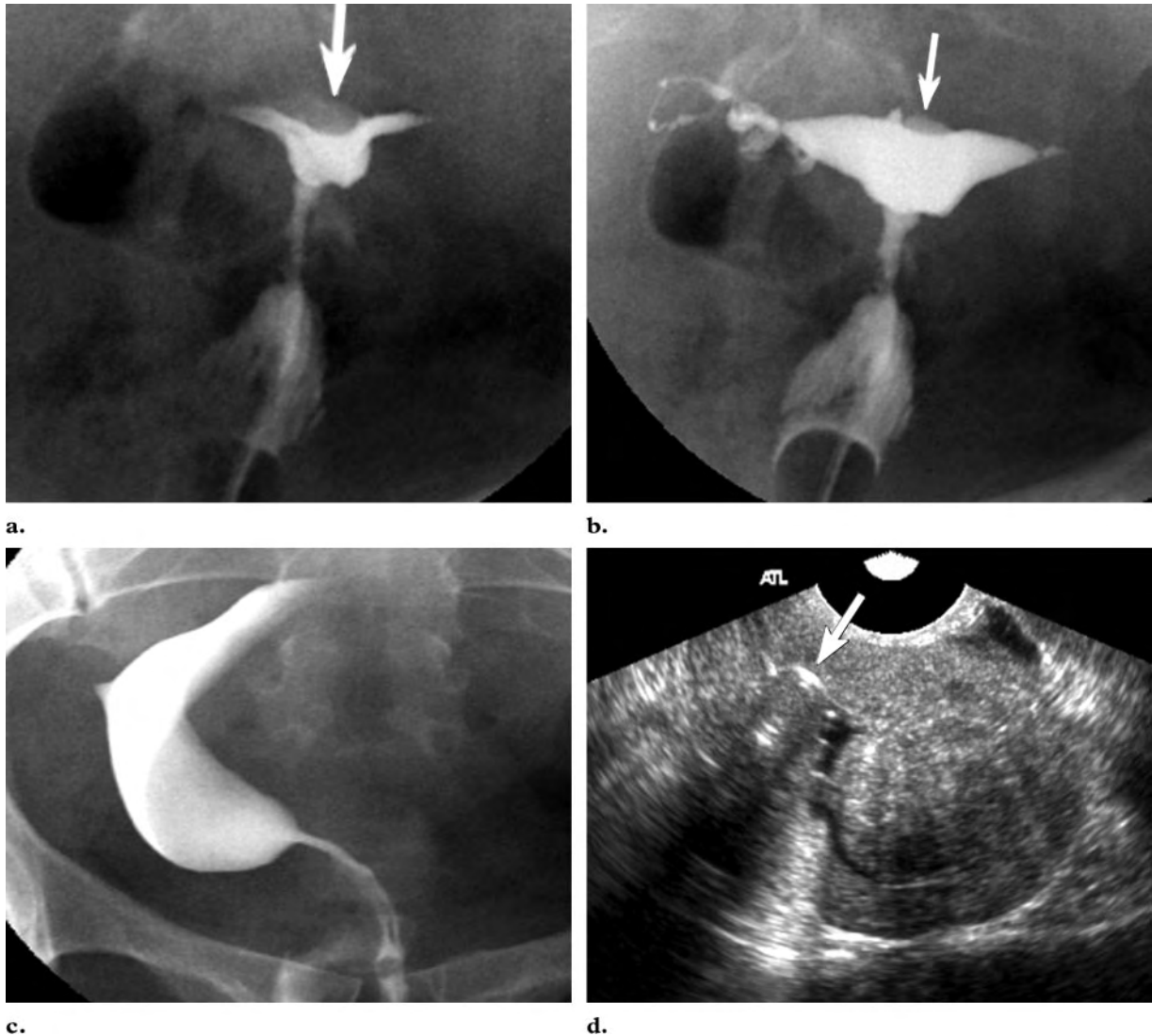
Endometrial polyps are focal overgrowths of the endometrium. They usually manifest as well-defined filling defects and are best seen during the early filling stage. Small polyps may be obscured when contrast material completely fills the uterine cavity and may be indistinguishable from a small submucosal myoma. Sonohysterography has become the preferred method of imaging endometrial polyps. Sonohysterography is similar to HSG. A catheter is inserted into the cervix, and sterile saline solution is instilled to distend the endometrial cavity while scanning transvaginally. The saline solution increases the conspicuity of masses, which are surrounded by fluid and are easily identified (Fig 8). For example, a connection to the endometrium can sometimes be seen with pedunculated polyps. Color Doppler US can then be used to identify the central vascular stalk of the polyp.



**Figure 8.** Endometrial polyp. Sagittal sonohysterogram shows a large, well-defined mass in the fundus arising from the anterior aspect of the endometrium. Note the cystic area in the lower portion of the polyp.

### Abnormalities of Uterine Contour

Leiomyomas are benign tumors of the smooth muscle of the uterus. They may be in subserosal, intramural, or submucosal locations within the uterine wall. Leiomyomas manifest as well-defined filling defects at HSG and can have a variety of appearances depending on their size and their location within the uterus (Fig 9).



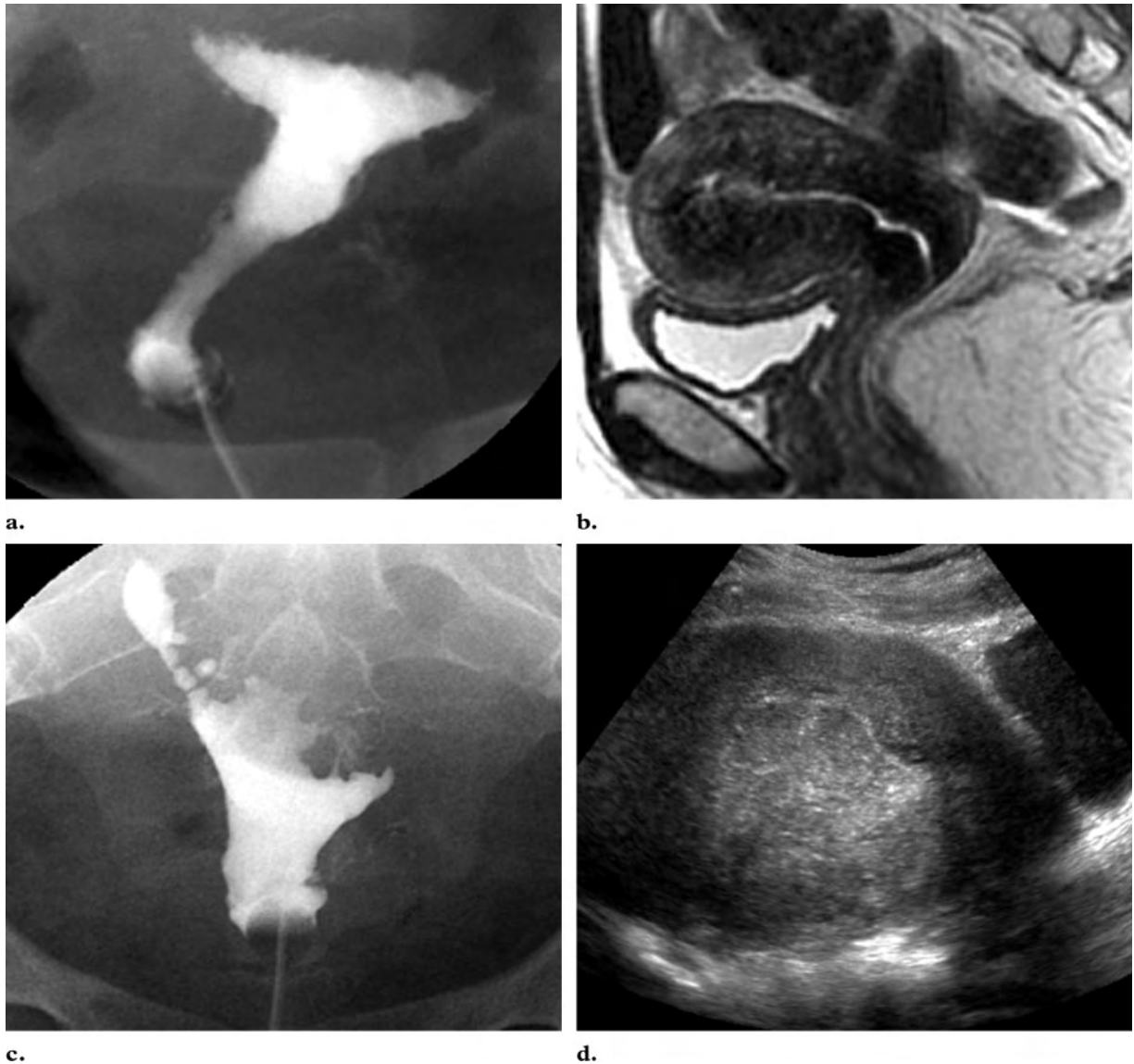
**Figure 9.** Leiomyomas. (a) Spot radiograph obtained during the early filling stage shows a well-defined filling defect (arrow) in the fundus. (b) On a spot radiograph obtained with the uterus more distended with contrast material, the fibroid (arrow) is less apparent. (c) Spot radiograph obtained in a different patient reveals a large leiomyoma distorting the endometrial cavity as it drapes over a mass in the left myometrium. (d) Sonohysterogram obtained in a third patient shows a retroverted uterus with fluid outlining a submucosal mass in the fundus. The balloon of an HSG catheter (arrow) is seen in the lower uterine segment.

#### Teaching Point

Only submucosal myomas are depicted at HSG. Small myomas, like polyps, can best be seen during early contrast material filling of the uterus but may be obscured when the uterus is completely opacified. Large myomas can distort the size and shape of the uterine cavity (Fig 9c, 9d).

Adenomyosis is a condition in which endometrium extends into the myometrium. Adenomyosis can be diffuse or focal in the uterus. A focal area with a mass-like configuration has been termed an adenomyoma. Adenomyosis may be imaged with HSG if nests of endometrial tissue

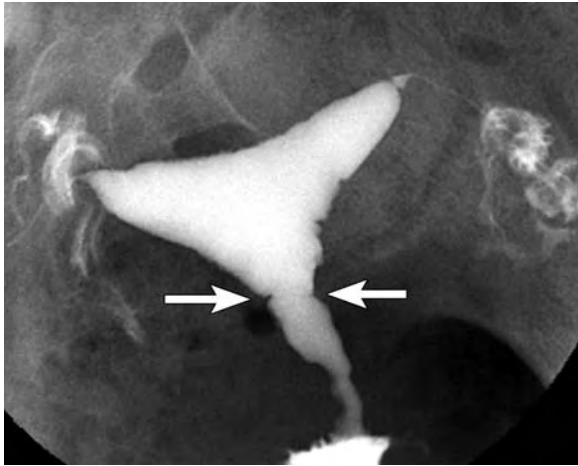
connect to the uterine cavity. At HSG, adenomyosis appears as small diverticula extending into the myometrium (Fig 10a, 10c). Because adenomyosis generally manifests as pelvic pain or abnormal bleeding, it is more commonly detected with MR imaging or US and is an incidental finding at HSG performed in an infertile woman. At



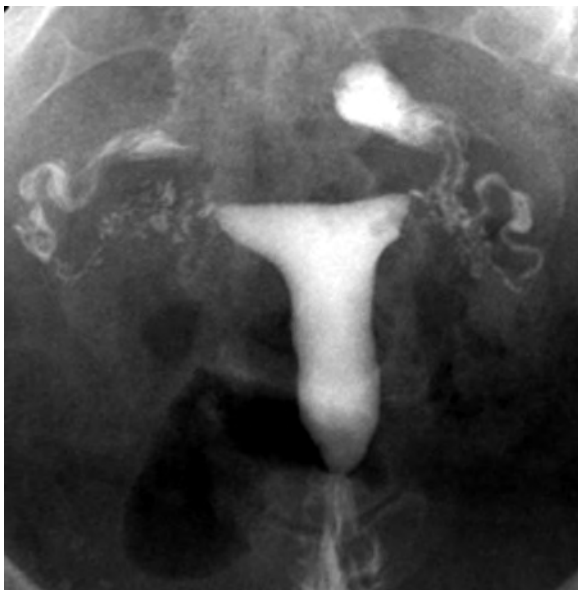**Figure 10.** (a, b) Diffuse adenomyosis. (a) Spot radiograph shows irregularity of the uterine contour with small outpouchings of contrast material, findings that represent diffuse adenomyosis. (b) Sagittal T2-weighted MR image shows thickening of the junctional zone to more than 1 cm, especially in the anterior fundus. (c, d) Focal adenomyosis. (c) Spot radiograph demonstrates an irregular mass-like filling defect in the fundus with small contrast material-filled diverticula, findings that represent focal adenomyosis. (d) Transabdominal US image shows thickening of the posterior uterine fundus with a heterogeneous echotexture in the area of focal adenomyosis (cf c).

MR imaging, adenomyosis appears as thickening of the junctional zone to 1 cm or more (Fig 10b). At US, it manifests as diffuse or focal areas of heterogeneous myometrial echotexture (Fig 10d). MR imaging is the optimal imaging modality when adenomyosis is a clinical consideration.

Many women who present for HSG report a history of uterine surgery. For example, a history of cesarean section is common in younger women (Fig 11). Women who have undergone myomectomy for a submucosal fibroid can have irregularity of the uterine contour in the myomectomy bed or, rarely, can develop a small diverticulum at the site.



**Figure 11.** Cesarean section scar. Spot radiograph shows the uterine incision from a cesarean section (arrows) in the typical location (ie, oriented transverse in the lower uterine segment in the region of the isthmus). At HSG, a cesarean section scar can have a linear appearance (as in this case) or can occasionally manifest as a wedge-shaped outpouching or diverticulum.



**Figure 12.** SIN. Spot radiograph demonstrates SIN as small outpouchings or diverticula from the isthmic portion of the fallopian tubes. SIN can be either unilateral or (as in this case) bilateral.

### Fallopian Tubes

The fallopian tubes serve as the passageway for the ovum to travel from the ovary to the uterus. They are 10–12 cm in length and course along

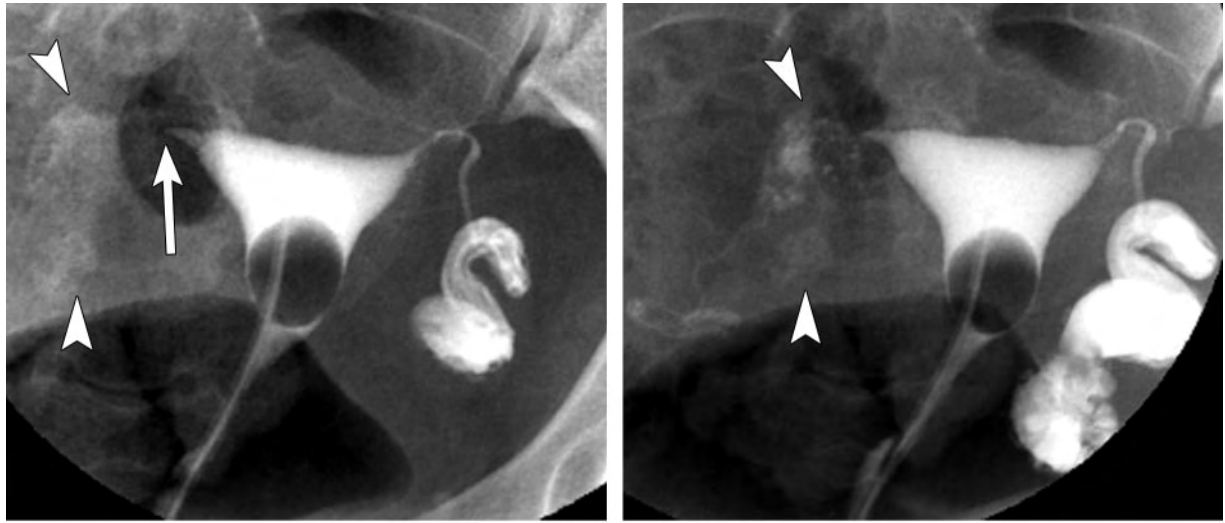
the superior aspect of the broad ligament (7). Each fallopian tube can be divided into three segments radiographically. The interstitial or cornual region is the short segment that traverses the muscular wall of the uterus. The isthmic portion is the longest of the three segments and is the narrow segment between the interstitial and ampullary regions. The ampullary portion is the widened region near the ovary. The fimbriated part is the funnel-shaped end of the tube and is not usually seen at HSG.

**HSG is the best method for visualizing and evaluating the fallopian tubes.** Contrast material-enhanced sonohysterography has been suggested as a means of assessing tubal patency (8,9). A contrast agent is instilled into the uterus through an HSG catheter and is imaged as it exits the patent tube. However, US contrast agents are not approved by the U.S. Food and Drug Administration and are not widely used in the United States. In addition, contrast-enhanced sonohysterography does not allow visualization of the entire tube. MR hystero-graphy with a heavily T2-weighted sequence (a procedure that is similar to MR cholangiopancreatography) has also been suggested for visualization of the fallopian tubes (10). However, the size of the normal fallopian tube is at or below the resolution of most MR imagers (11). Moreover, even if the tube is visualized, MR hystero-graphy does not help assess tubal patency. Instillation of saline solution or water through an HSG catheter in conjunction with MR hystero-graphy is possible, but this procedure has not gained wide acceptance (10).

At HSG, the fallopian tubes should appear as thin, smooth lines that widen in the ampullary portion (Fig 1c). The isthmic portion has been likened to a piece of spaghetti in appearance. The fallopian tubes vary in location within the pelvis and in degree of tortuosity. There should be free spillage of contrast material into the peritoneal cavity (Fig 1d). Tubal abnormalities seen at HSG can be either congenital or due to spasm, occlusion, or infection.

Salpingitis isthmica nodosum (SIN) is of unknown cause. It is associated with infertility, PID, and, occasionally, ectopic pregnancy (12). SIN appears as small outpouchings or diverticula from the isthmic portion of the fallopian tube and can affect one or both tubes (Fig 12).

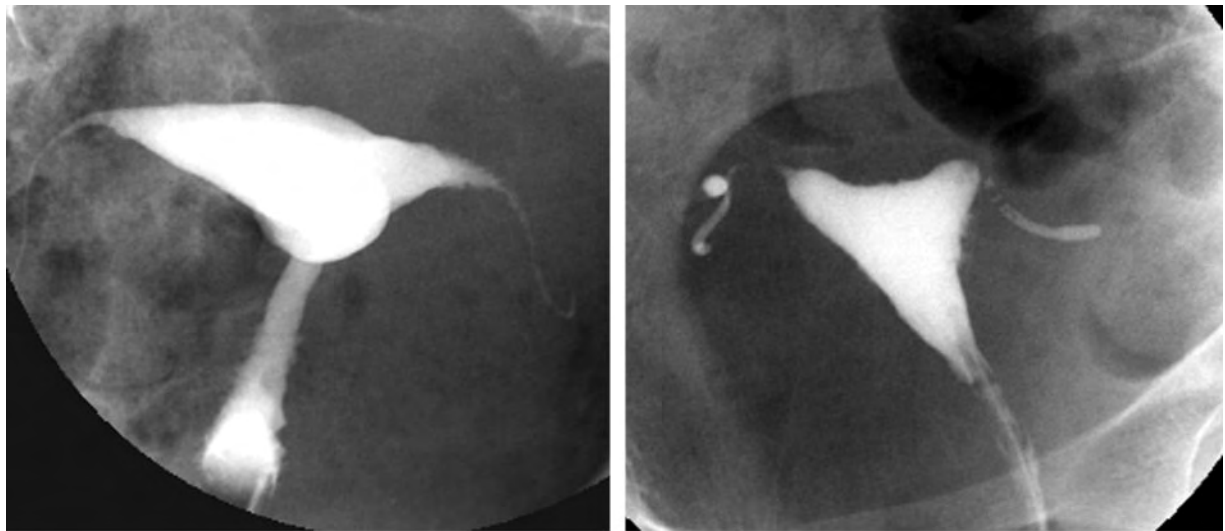
**Teaching Point**



a.

b.

**Figure 13.** Cornual spasm. (a) On an HSG spot radiograph obtained during the early filling stage of the uterus, the right fallopian tube does not opacify beyond the cornual portion (arrow), whereas the left fallopian tube opacifies to the ampullary portion. Arrowheads indicate amorphous calcifications on the right side of the pelvis. These calcifications were also present on the scout image (not shown). (b) On a spot radiograph obtained after the instillation of additional contrast material, the right fallopian tube opacifies to the ampullary portion. Right-sided SIN and a left-sided hydrosalpinx are also noted. Amorphous calcifications (arrowheads) are again seen on the right side of the pelvis.



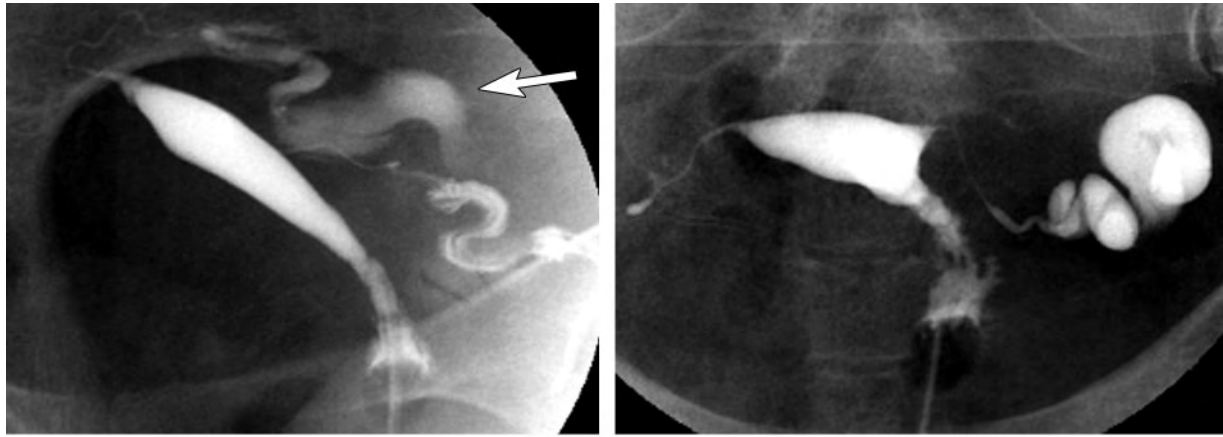
a.

b.

**Figure 14.** Tubal occlusion. (a) Spot radiograph demonstrates abrupt cutoff of the left fallopian tube. (b) Spot radiograph demonstrates cutoff of contrast material in the isthmic portions of both fallopian tubes, with bulbous dilatation of the distal aspects of the opacified portions. These findings can be seen with postsurgical occlusion (eg, following tubal ligation).

The cornual portion of the fallopian tube is encased by the smooth muscle of the uterus. If there is spasm of the muscle during HSG, one or

both tubes may not fill beyond the interstitial portion (Fig 13a). At radiography, tubal spasm cannot be distinguished from tubal occlusion. Administration of a spasmolytic agent such as glucagon can occasionally result in uterine muscle

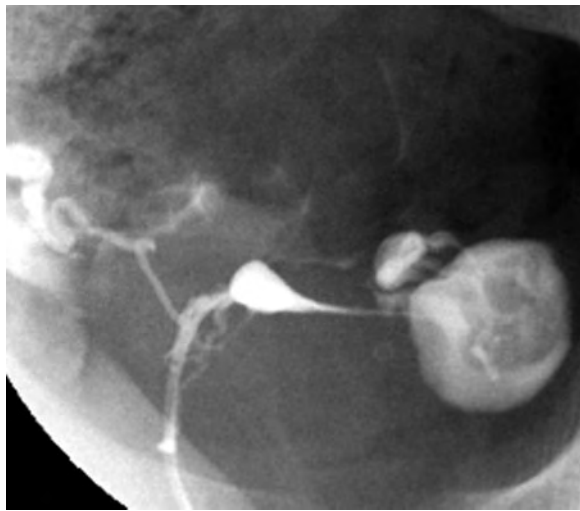

a.

b.

**Figure 15.** Hydrosalpinx. (a) Steep right oblique spot radiograph shows dilatation of the ampullary portion of the right fallopian tube (arrow). The left fallopian tube is normal in caliber. Mucosal folds are visible in the ampullary portions of both fallopian tubes, a finding that helps confirm the presence of contrast material within the tubes.

(b) Spot radiograph shows dilatation of the ampullary portion of the left fallopian tube, a finding that is consistent with a hydrosalpinx. No contrast material spillage is seen on the left side. The right fallopian tube is abruptly cut off, a finding that is consistent with previous tubal ligation.



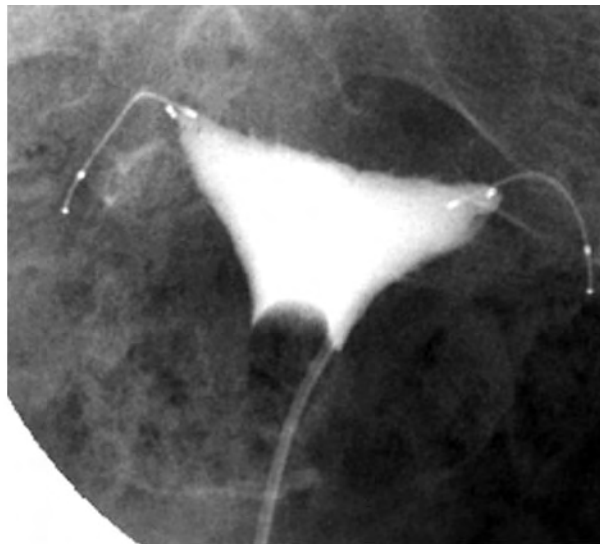
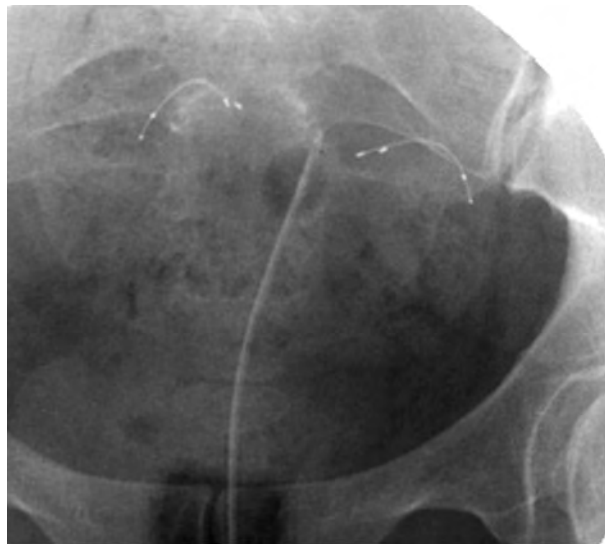**Figure 16.** Peritubal adhesions. Spot radiograph demonstrates a round collection of contrast material adjacent to the left fallopian tube, a finding that suggests peritubal adhesions. Note the free contrast material spillage on the right side.

relaxation and consequent tube opacification (Fig 13b), thereby helping differentiate cornual spasm from true occlusion (13).

PID is the most common cause of tubal occlusion leading to infertility (14). Although active pelvic infection is a contraindication for HSG, the residua of previous episodes can be seen at HSG.

Tubal occlusion manifests as an abrupt cutoff of contrast material with nonopacification of the more distal fallopian tube, can be unilateral or bilateral, and can affect any portion of the tube (Fig 14). If the blockage is in the ampullary portion, the tube may dilate, forming a hydrosalpinx (Fig 15). Another sequela of PID is scarring in the peritoneal cavity surrounding the fallopian tube. Peritubal adhesions prevent contrast material from flowing freely around the bowel loops and most commonly manifest as loculation of the contrast material around the ampullary portion of the tube (Fig 16).

Occasionally, HSG is performed for postoperative evaluation of the fallopian tubes—for example, documentation of tubal occlusion following tubal ligation. Such occlusion appears as an abrupt termination of the tube at the surgical site or mild bulbous expansion of the tube with cutoff (Figs 14b, 15b). HSG may also be performed to demonstrate tubal patency without extravasation of contrast material after reversal of a ligation procedure. A new irreversible occlusion device called Essure (Conceptus, San Carlos, Calif), was recently introduced. This soft, flexible microinsert is placed hysteroscopically into each fallopian tube, thereby obviating laparoscopy. The microinsert induces scar tissue formation around itself



a.

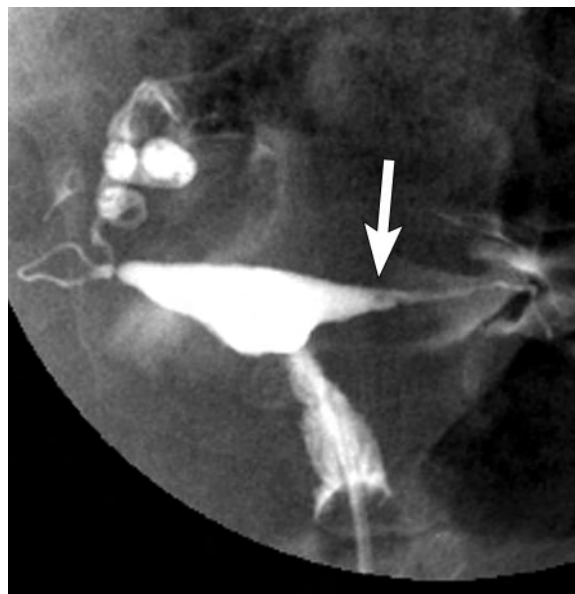b.

**Figure 17.** Irreversible tubal occlusion with a microinsert. (a) Scout radiograph obtained prior to the instillation of contrast material shows a microinsert that has been placed hysteroscopically into the proximal fallopian tube. (b) Radiograph obtained after instillation shows no contrast material filling of the fallopian tube beyond the microinsert, a finding that helps document tubal occlusion.

after a few months. At that time, HSG is usually performed to evaluate for tubal occlusion (Fig 17) (15).

Tubal polyps are rare. They represent ectopic endometrial tissue located in the interstitial portion of the tube. Tubal polyps manifest as smooth, rounded filling defects in this location, without concomitant dilatation or tubal occlusion. These polyps are less than 1 cm in diameter and can be either unilateral or bilateral (Fig 18). Women with tubal polyps are asymptomatic, and the association of these polyps with infertility has not been established (16).

Ectopic pregnancy should not be seen at HSG, given the timing of the study during the proliferative phase of the menstrual cycle. Infrequently, pregnant women do undergo HSG, and if an ectopic pregnancy is present, it may manifest as a tubal filling defect. US should serve as the first-line imaging modality for the evaluation of a suspected ectopic pregnancy.



**Figure 18.** Tubal polyp. Spot radiograph shows a small filling defect (arrow) in the proximal left fallopian tube, a finding that typically represents a tubal polyp.

## Conclusions

HSG is a valuable tool in the evaluation of the uterus and fallopian tubes. Radiologists should become familiar with HSG technique, the interpretation of HSG images, and possible complications of this procedure.

## References

1. Society for Assisted Reproductive Technology; American Society for Reproductive Medicine. Assisted reproductive technology in the United States: 2000 results generated from the American Society for Reproductive Medicine/Society for Assisted Reproductive Technology Registry. *Fertil Steril* 2004;81(5):1207-1220.
2. Meden-Vrtovec H. Ovarian aging and infertility. *Clin Exp Obstet Gynecol* 2004;31(1):5-8.
3. Ott DJ, Fayez JA, Chen MYM. Techniques of hysterosalpingography. In: Ott DJ, Fayez JA, Zagoria RJ, eds. *Hysterosalpingography: a text and atlas*. 2nd ed. Baltimore, Md: Williams & Wilkins, 1998; 11-27.
4. Troiano RN, McCarthy SM. Mullerian duct anomalies: imaging and clinical issues. *Radiology* 2004;233(1):19-34.
5. Slezak P, Tillinger KG. The occurrence and significance of broad longitudinal folds in the uterine cavity at hystero-graphy. *Radiology* 1973;106:87-90.
6. Asherman JG. Traumatic intra-uterine adhesions. *J Obstet Gynaecol Br Emp* 1950;57:892-896.
7. Chen MYM, Zagoria RJ. Normal radiographic anatomy. In: Ott DJ, Fayez JA, Zagoria RJ, eds. *Hysterosalpingography: a text and atlas*. 2nd ed. Baltimore, Md: Williams & Wilkins, 1998; 29-30.
8. Reis MM, Soares SR, Cancado ML, Camargos AF. Hysterosalpingo contrast sonography (Hy-CoSy) with SH U 454 (Echovist) for the assessment of tubal patency. *Hum Reprod* 1998;13(11):3049-3052.
9. Killick SR. Hysterosalpingo contrast sonography as a screening test for tubal patency in infertile women. *J R Soc Med* 1999;92(12):628-631.
10. Rouanet De Lavit JP, Maubon AJ, Thurmond AS. MR hystero-graphy performed with saline injection and fluid attenuation inversion recovery sequences: initial experience. *AJR Am J Roentgenol* 2000; 175(3):774-776.
11. Hagspiel KD, Altes TA, Mugler JP, Brookeman JR. Magnetic resonance hystero-graphy and hysterosalpingography using hyperpolarized (3)He: demonstration of feasibility in an animal model. *J Magn Reson Imaging* 2000;12(6):1009-1013.
12. Ott DJ, Fayez JA. Tubal and adnexal abnormalities. In: Ott DJ, Fayez JA, Zagoria RJ, eds. *Hysterosalpingography: a text and atlas*. 2nd ed. Baltimore, Md: Williams & Wilkins, 1998; 90-93.
13. Winfield AC, Pittaway D, Maxson W, Daniell J, Wentz AC. Apparent cornual occlusion in hysterosalpingography: reversal by glucagon. *AJR Am J Roentgenol* 1982;139:525-527.
14. Sweet RL. Pelvic infections in infertility. In: Behrman SJ, Kistner RW, Patton GW, eds. *Progress of infertility*. 3rd ed. Boston, Mass: Little, Brown, 1988; 25-46.
15. Essure home page. Available at: [www.Essure.com](http://www.Essure.com). Accessed October 18, 2004.
16. Ubeda B, Paraira M, Alert E, Abuin RA. Hysterosalpingography: spectrum of normal variants and nonpathological findings. *AJR Am J Roentgenol* 2001;177(1):131-135.

## Hysterosalpingography: A Reemerging Study

*William L. Simpson, Jr, MD, et al*

RadioGraphics 2006; 26:419–431 • Published online 10.1148/rg.262055109 • Content Codes: GU OB

---

### Page 420

Hysterosalpingography (HSG) is the radiographic evaluation of the uterus and fallopian tubes and is used predominantly in the evaluation of infertility. Other indications for HSG include the evaluation of women with a history of recurrent spontaneous abortions, the postoperative evaluation of women who have undergone tubal ligation or reversal of tubal ligation, and the assessment of patients prior to myomectomy (Table).

### Page 420

There are two contraindications for HSG: pregnancy and active pelvic infection. The examination should be scheduled during days 7–12 of the menstrual cycle (day 1 being the first day of menstrual bleeding). The endometrium is thin during this proliferative phase, a fact that facilitates image interpretation and should also ensure that there is no pregnancy.

### Page 422

Uterine anomalies can be due to (a) congenital abnormalities of uterine shape, (b) luminal filling defects, or (c) abnormalities of uterine contour.

### Pages 425

Only submucosal myomas are depicted at HSG. Small myomas, like polyps, can best be seen during early contrast material filling of the uterus but may be obscured when the uterus is completely opacified.

### Page 427

HSG is the best method for visualizing and evaluating the fallopian tubes.